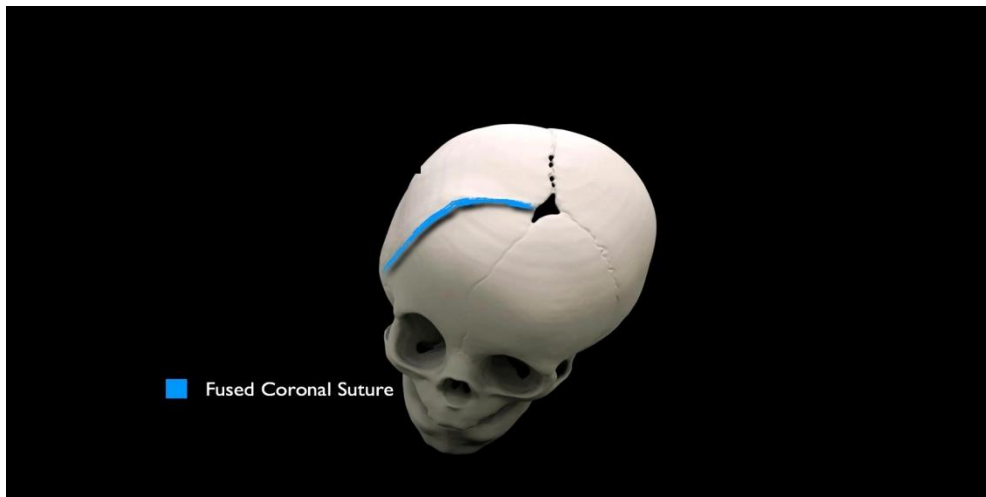

How 3D Printing helped save a child's life

Introduction

The applications of 3D printing are vast, as it is not just confined to experimentation anymore. Apart from the most obvious applications in the fields of architecture and engineering, 3D Printing is contributing to the medicine as well. This unorthodox methodology, though new, is proving to be very crucial.

Premise

A 4-year-old child (female) suffered from craniosynostosis, a congenital condition. In craniosynostosis, the joints of the skull fuse prematurely during the formative period (mostly infancy). The result of this abnormal fusing of joints leads to a deformed skull. There are some crevices and cavities left in the skull, which restricts the normal growth on the brain.



As a result of this deformity, the brain growth and function is affected due to increased intracranial pressure, and can lead to impairment of the visual, aural, and olfactory faculties. It can cause irreversible nerve damage and can result in mental retardation.

Proposed Conventional Surgical Solution

The 4-year-old patient was advised a reconstructive surgery in order to counter the effects of the maldevelopment of the skull. The goals of the surgery were to relieve the intracranial pressure on the brain for the brain to grow and function normally, to make sure that the brain has enough space in the skull to develop, and also to improve the appearance of the child's head.

[Divide By Zero Technologies](http://DivideByZeroTechnologies.com)



The consequential steps leading to the advised reconstructive surgery include 3D imaging of the patient's skull by CT scans, well-documented markings on paper, and an estimate of the cuts on the bones, based on the CT scan imaging. Since the "3D images" are still essentially 2D in nature, the surgeons rely on their imaginative visualization for the estimated incisions in the bones of the skull.

Drawbacks of the conventional surgical solution

Though the proposed surgical solution was the only way to correct the deformed skull, the preparatory/imaging procedures have their drawbacks that can compromise the calculated precision of the surgery. A few obstacles have been listed below:

- As mentioned earlier, the imaging techniques are essentially two dimensional and leave a lot to the surgeon's discretion and experience.
- Due to the lack of exact proportions, the decision of exactly how to initiate the surgery is sometimes taken on the operation table.
- It is very difficult for the post-graduate medical students to understand the nuances of the procedure due to lack of precision and their experience.
- The CT scan imaging has its limitations when it comes to visualizing the dimensions of the skull precisely.
- The lengths of the sutures are sometimes not depicted accurately on plain radiographs.

How 3D Printing helped in the exact imaging of the deformed skull

To combat all the drawbacks presented by the current imaging techniques, 3D printing was applied as the solution to get a scaled replica of the deformed skull. The procedure of having the skull 3D printed and the challenges that were faced are mentioned below:

The procedure:

- The deformed skull underwent CT scan imaging. These images were converted into a 3D file.
- The 3D files were post-processed to get rid of the noise, for the print to be error-free.
- The file was 3D printed.
- Mock surgery was performed on the replica of the patient's deformed skull.

The challenges:

1. The noise in the 3D file

One of the primary challenges was to do away with the noise from the 3D file from the CT scan imaging. The noises in the file may have resulted in erroneous or irrelevant printing.


Solution: Post-processing on the 3D files got rid of the noise. The file before the noise is depicted on the left-hand side and after processing, the actual image that is to be printed is seen in the figure on the right-hand side.

[Divide By Zero Technologies](http://DivideByZeroTechnologies.com)

2. Long print time interrupted by power cuts

The estimated total printing time was about 9 hours. This wouldn't have been a problem in itself, except due to the frequent power cuts in Pondicherry, it was a problem to continue printing. The 3D printer would have restarted at the beginning.

Solution: An auto resume code was developed to tackle this issue. This would help the 3D printer to start off at the point it was printing last. Thus after every power cut, the printer would simply resume the printing where it had halted before the power cut.



3. Long print time interrupted by power cuts

The estimated total printing time was about 9 hours. This wouldn't have been a problem in itself, except due to the frequent power cuts in Pondicherry, it was a problem to continue printing. The 3D printer would have restarted at the beginning.

Solution: An auto resume code was developed to tackle this issue. This would help the 3D printer to start off at the point it was printing last. Thus after every power cut, the printer would simply resume the printing where it had halted before the power cut.

4. The thickness of the wall

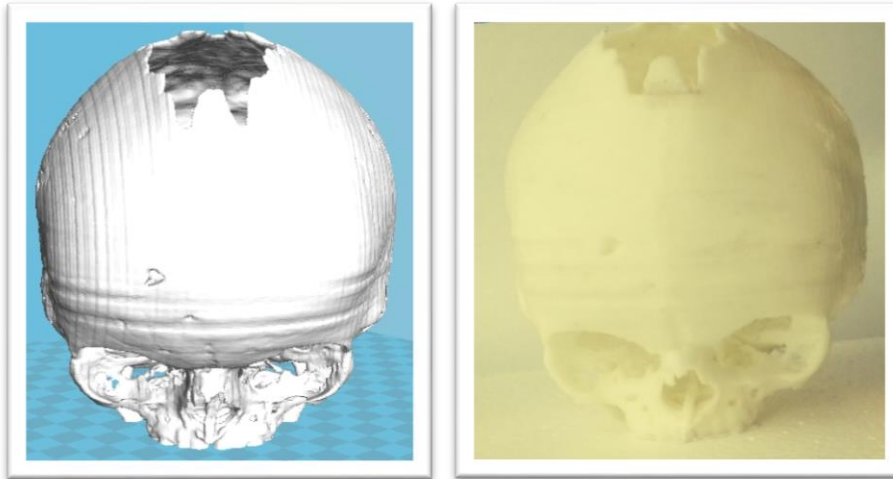
FDM/FF can print as thin as 1 mm. However, given the age of the patient, the deformed skull was of 0.7 mm thickness. The challenge here was to print something thinner than the permissible limit.

Solution: A special 0.2 mm (200 microns) nozzle was conceived and developed in order to achieve the skull wall thickness as low as 0.7 mm. With the new nozzle, the lowest thickness of the printing could be 0.4mm.

The final product of the 3D printing:

After curbing the obstacles and resolving the aforementioned challenges, the 3D printer was engaged in the actual printing, based on the processed 3D file from the CT scans.

The 3D file image can be seen on the left-hand side, while the actual finished product is seen in the image on the right-hand side.



Final Steps:

After the deformed skull was 3D printed to the precise scale and thickness, mock surgery was performed in order to determine the actual plan of action for the patient.

Current Scenario:

The patient was operated upon on the 1st of October for craniosynostosis, and she is now recovering and doing fine with regards to her cranial condition.